

3D Fibroid classification

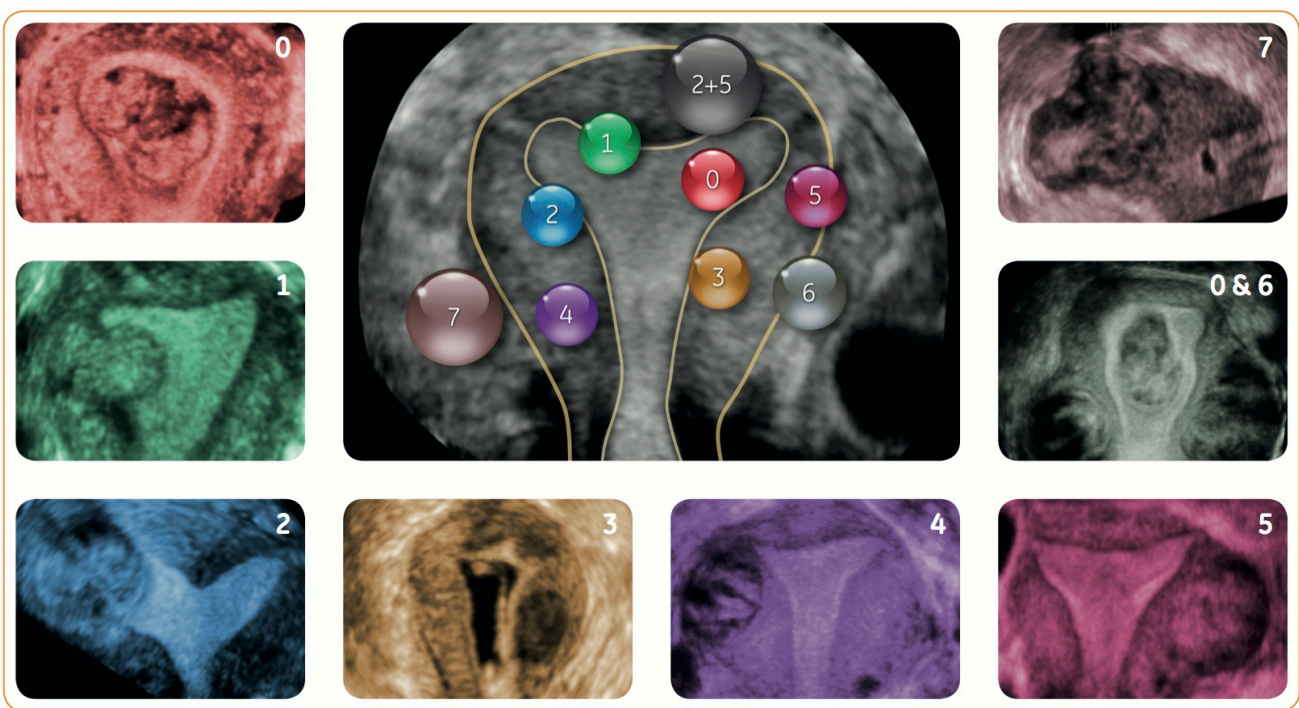
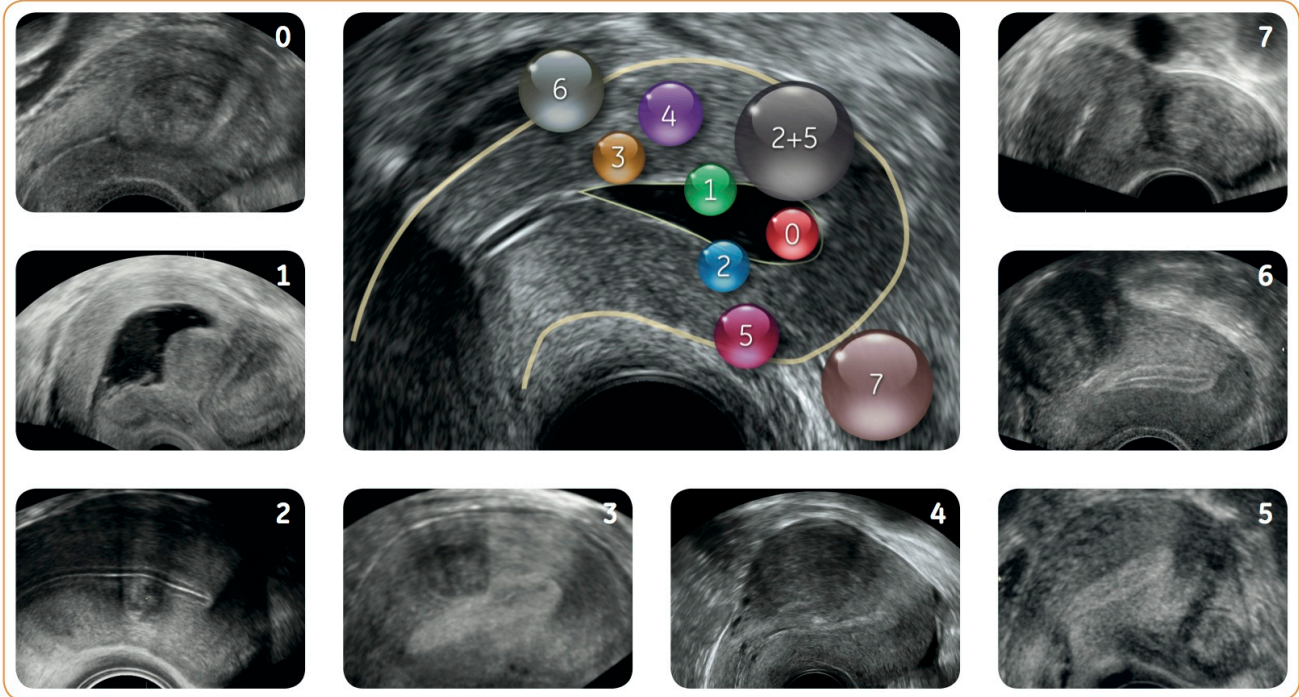


Bernard Benoit
Centre Hospitalier Princesse
Grace, Monaco

Jean Marc Levaillant
Kremlin Bicêtre Hospital, France

Guillaume Legendre
Kremlin Bicêtre Hospital, France

Hervé Fernandez
Kremlin Bicêtre Hospital, France



SUBMUCOSAL
0 Pedunculated intracavitary
1 < 50% intra mural
2 ≥ 50% intra mural

OTHER
3 contact endometrium, 100% intra mural
4 intra mural
5 subserosal ≥ 50% intra mural
6 subserosal < 50% intra mural
7 subserosal pedunculated
8 other (specify e.g. cervical, parasitic)

HYBRID
2-5 submucosal and subserosal, each with less than half the diameter in the endometrial and peritoneal cavities, respectively

DOC1378264